

Altered Alignment of the Shoulder Girdle and Cervical Spine in Patients With Insidious Onset Neck Pain and Whiplash-Associated Disorder

Harpa Helgadóttir, Eythor Kristjánsson, Sarah Mottram,
Andrew Karduna, and Halldor Jonsson, Jr.

Clinical theory suggests that altered alignment of the shoulder girdle has the potential to create or sustain symptomatic mechanical dysfunction in the cervical and thoracic spine. The alignment of the shoulder girdle is described by two clavicle rotations, i.e., elevation and retraction, and by three scapular rotations, i.e., upward rotation, internal rotation, and anterior tilt. Elevation and retraction have until now been assessed only in patients with neck pain. The aim of the study was to determine whether there is a pattern of altered alignment of the shoulder girdle and the cervical and thoracic spine in patients with neck pain. A three-dimensional device measured clavicle and scapular orientation, and cervical and thoracic alignment in patients with insidious onset neck pain (IONP) and whiplash-associated disorder (WAD). An asymptomatic control group was selected for baseline measurements. The symptomatic groups revealed a significantly reduced clavicle retraction and scapular upward rotation as well as decreased cranial angle. A difference was found between the symptomatic groups on the left side, whereas the WAD group revealed an increased scapular anterior tilt and the IONP group a decreased clavicle elevation. These changes may be an important mechanism for maintenance and recurrence or exacerbation of symptoms in patients with neck pain.

Keywords: neck pain, whiplash, scapula, posture

Clinical theory suggests that altered alignment of the shoulder girdle has the potential to create or sustain symptomatic mechanical dysfunction in the cervical and thoracic spine by inducing compressive, rotational, and shear forces in the tissues (Behrsin & Maguire, 1986; Janda, 1994; Jull et al., 2004b, 2008). Until now the alignment of the shoulder girdle in patients with cervical disorders has been investigated only by measuring the upward and forward displacement of the acromion with reference to the 7th cervical spinous process or by angular measurements using these landmarks. These studies evaluating the protraction/retraction and elevation/depression of the shoulder girdle do not take into consideration the alignment of the thoracic cage, nor do they measure scapular orientation (Braun, 1991; Szeto et al., 2002; Yip et al., 2008).

This study applies the definition of body segment and joint coordinate system proposed by the Standardization and Terminology Committee of the International Society

Harpa Helgadóttir (*Corresponding Author*) and Halldor Jonsson, Jr., are with the Faculty of Medicine, University of Iceland, Reykjavik, Iceland. Eythor Kristjánsson is with FORMI, Ullevål, Oslo University Hospital, Norway. Sarah Mottram is with KC International Ltd, Chichester, West Sussex, UK. Andrew Karduna is with Department of Human Physiology, University of Oregon, Eugene, OR, USA.

of Biomechanics. This includes measuring the three-dimensional orientation of the shoulder girdle described by two clavicle rotations—elevation and retraction, and by three scapular rotations—upward rotation, internal rotation, and anterior tilt (Figure 1) (Karduna et al., 2001; Wu et al., 2005).

The alignment of the shoulder girdle varies considerably between individuals within the general population. In general, the clavicles should be symmetrical, elevate around 6 degrees and retract around 20 degrees at the sternoclavicular joint (Ludewig et al., 2009). The scapula sits between the second and the seventh ribs on the posterior thoracic wall (Williams & Warwick, 1980), approximately 8 cm lateral to the spinous processes (Sobush et al., 1996). The optimum alignment of the scapula with the arms by the side has been described as the mid-position of the scapula between the individual available range of upward and downward rotation, external and internal rotation, and posterior and anterior tilt (Mottram et al., 2009). This has been described as the “scapula neutral position.” There is minimal support from the passive osteo-ligamentous system in this position so the myofascial structures, in particular the trapezius and the serratus anterior, are considered to have an important role (Mottram et al., 2009).

Potential mechanisms that can alter the alignment of the shoulder girdle include pain, tightness in the soft

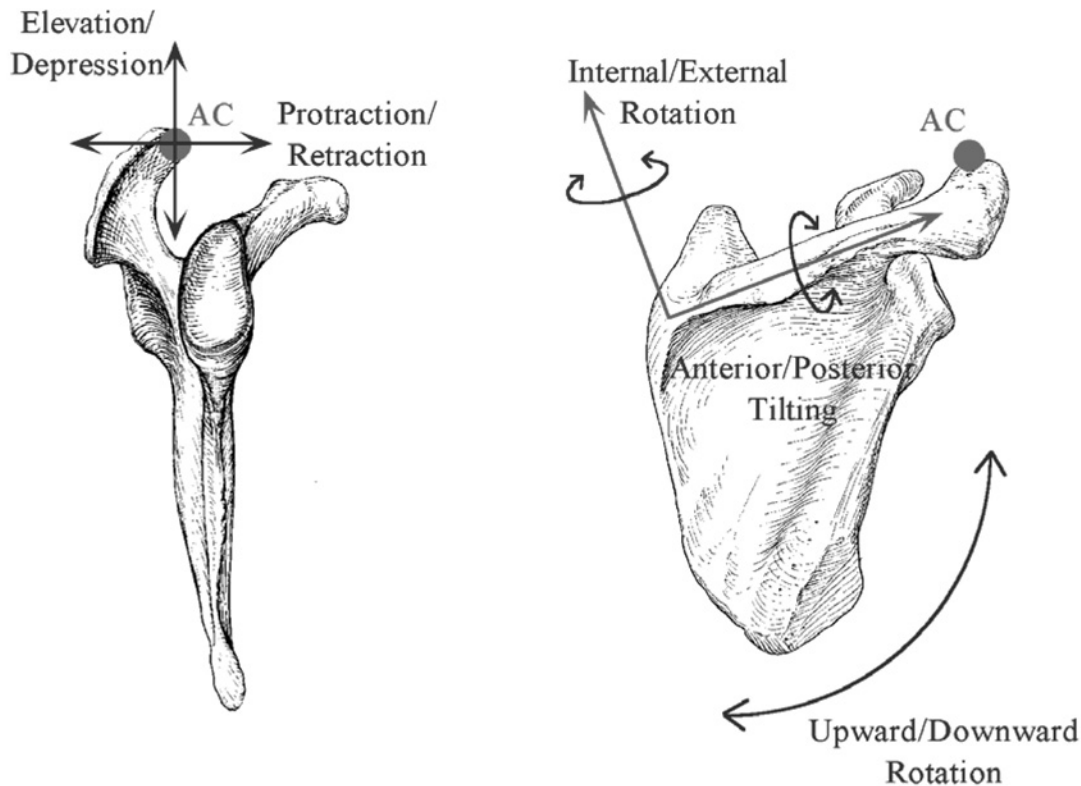


Figure 1 — Clavicle and scapular rotations.

tissues, imbalances in muscle activity or strength, muscle fatigue, and the cervical and thoracic curves (Kebaetse et al., 1999; Michener et al., 2003; Sahrman, 2002). The presence of pain is associated with altered muscle activity in the trapezius and the serratus anterior muscles (Fall et al., 2004a, 2007a; Ludewig & Cook, 2000; Sterling et al., 2001). Paralysis of these muscles due to injury to the accessory nerve and the long thoracic nerve illustrates their contribution in maintaining optimum scapular orientation. Trapezius paralysis results in a scapular orientation characterized by a reduced elevation and retraction of the clavicle, and increased upward rotation of the scapula. Serratus anterior paralysis results in increased elevation of the clavicle, medial translation, and downward rotation of the scapula (Kuhn et al., 1995). Tightness and overactivity of both the levator scapulae and the rhomboid muscles tend to adduct, downwardly rotate, and elevate the most medial part of the scapula (Behrsin & Maguire, 1986; Sahrman, 2002). The pectoralis minor, the biceps brachii (caput brevis), and the coracobrachialis muscles, which attach to the coracoid process, can create forward pull on the scapula causing anterior tilting of the scapula and protraction of the clavicle and along with the pectoralis major; the pectoralis minor may also cause downward rotation of the scapula (Kibler & McMullen, 2003; Williams & Warwick, 1980).

Changes in cervical and thoracic alignment (Kibler & McMullen, 2003) as well as slouched posture are also known to contribute to altered alignment of the scapula (Finley & Lee, 2003; Kebaetse et al., 1999). Altered cervical alignment is considered to be an important mechanism influencing cervical (Edmondston et al., 2005; Szeto et al., 2005b) and scapular kinematics (Kibler & McMullen, 2003; Thigpen et al., 2010). Evidence is emerging demonstrating that cervical alignment is associated with the efficient function of the deep cervical flexors (Fall et al., 2007b), the trapezius and the serratus anterior muscles (Weon et al., 2010). However, there is conflicting evidence as to whether there is a difference in cervical alignment between patients with neck pain and asymptomatic subjects (Edmondston et al., 2007; Harrison et al., 2004; Yip et al., 2008). Association between prolonged neck pain and more flexed cervicothoracic posture has been reported in adolescents (Straker et al., 2009) but association has not been found between changes in the thoracic curve and cervical spine disorders in adults (Szeto et al., 2005a).

The aim of the study was to determine whether there is a pattern of altered alignment of the shoulder girdle, and the cervical and thoracic spine, at rest, in patients with cervical spine disorders. The hypothesis is that patients with cervical spine disorders demonstrate an altered

alignment of the shoulder girdle and the alignment of the cervical and thoracic spine.

Methods

Subjects

The current study included patients with insidious onset neck pain (IONP) and patients with whiplash-associated disorder (WAD) grade II, following a motor vehicle accident (Spitzer et al., 1995), since a difference may exist in impairments between these groups. A difference has been observed between these two groups of patients in the sagittal configuration of the cervical spine (Kristjansson & Jonsson, 2002), the fatty infiltration in the cervical extensor muscles (Elliott et al., 2008), the activity of the trapezius muscle, and the level of pain and disability (Falla et al., 2004a; Nederhand et al., 2002). Twenty-one subjects with IONP (19 women and 2 men) and twenty-three subjects with WAD (20 women and 3 men) were recruited at physical therapy clinics, on a voluntary basis, in the Reykjavik municipal area. This study was approved by the Bioethics Committee of Landspítali University Hospital and all subjects signed a consent form. A sample of convenience consisting of 20 asymptomatic subjects (17 women and 3 men) served as a control group (Table 1). All subjects were right handed. The subjects in the control group were selected to match the subjects in the symptomatic groups, according to their height, weight, age, gender, and physical activity level. Physical activity level was assessed by asking whether the subject engaged in some kind of physical activity on regular bases (sports, exercises etc.). If the answer was yes, the subject was asked what kind of physical activity and how many times per week. Demographic information (height, weight, age, gender, and physical activity level) were collected. Disability was measured by the Neck Disability Index (NDI), which is a self-reporting questionnaire (Vernon & Mior, 1991). Pain intensity was evaluated with a 10-cm Visual Analog Scale (VAS) anchored by *no pain* and *pain as bad as it can be*. The VAS was used to indicate the average intensity of neck pain experienced over the past seven days.

Inclusion criteria for the pain groups were age 18–55, a score of at least 10 on the NDI, and neck symptoms of more than six months in duration. Score below 10 on the NDI are scored as “no disability” (Vernon & Mior, 1991) and symptoms that have lasted more than six months are considered chronic (Hartling et al., 2001). Subjects were allocated to one of two groups: Group 1 included subjects with IONP who had no history of any accident or whiplash injury; Group 2 included subjects diagnosed with a WAD that had no history of symptoms in the neck area before the accident. A third group included the controls (Group 3), who were age 18–55 with neither cervical nor shoulder dysfunction. The cervical spine was examined by a trained physical therapist to confirm the presence or absence of cervical segmental joint dysfunction in patients with neck pain and controls, respectively. The glenohumeral joints were examined for pain, restriction, and impingement signs (Magee, 1987). Subjects were excluded if they had any known pathology or impairment in the shoulder joint, history of head injury or spinal fractures, systemic pathology, and serious psychological condition.

Before initiating the study, a sample of 20 subjects per group was calculated to provide 80% power to detect differences of 3 degrees between the groups. Calculations were based on our judgment of what are clinically meaningful differences.

Instrumentation and Measurements

Equipment. Three-dimensional kinematic data were collected at 40 Hz with the Polhemus 3-Space Fastrak device (Polhemus Colchester, VT), which has an accuracy of 0.8 mm and 0.15°. The device consisted of a global transmitter, three sensors, and a digitizing stylus, all of which were hardwired to a system electronic unit. The electronic unit determined the relative orientation and position of the digitizer and the sensors through the electromagnetic field emitted by the global transmitter. Information collected by the Fastrak system was sent to a computer with a software system developed by KINE (Hafnarfjörður, Iceland).

Table 1 Demographic details of the three groups

	Control Group			IONP Group			WAD Group		
	Women (n = 17); Men (n = 3)			Women (n = 19); Men (n = 2)			Women (n = 20); Men (n = 3)		
	Mean	SD	Range	Mean	SD	Range	Mean	SD	Range
Age (years)	29.70	7.75	21–51	35.23	8.41	25–54	33.37	9.58	18–50
Height (cm)	171.83	7.77	155–188	170.5	6.07	158–183	170.07	5.26	160–180
Weight (kg)	69.30	10.23	56–100	73.01	16.25	53–128	70.63	10.38	51–92
NDI	0	0	0	29.09	9.77	12–49	38	18.74	12–80

Evaluation of Shoulder Girdle Alignment. For evaluation of the alignment of the shoulder girdle, the study used the definition of body segment and joint coordinate system for the upper extremity proposed by the International Society of Biomechanics. These coordinate systems were defined using digitized anatomical landmarks to evaluate clavicle and scapular orientation (Wu et al., 2005). The digitizing stylus connected to the magnetic tracking device was used to manually digitize the coordinates of the landmarks listed in Table 2. All landmarks were palpable except for the center of glenohumeral rotation (GH). The GH was estimated by moving the humerus through short arcs (<45 degrees) of midrange glenohumeral motion. The GH was defined as the point on the humerus that moved the least with respect to the scapula when the humerus was moved and was calculated using a least-squares algorithm (Biryukova et al., 2000; Harryman et al., 1990). Based on standard matrix transformation methods, the global axes defined by the sensors of the Fastrak device were converted to anatomically defined axes derived from the digitized bony landmarks (Karduna et al., 2001).

Table 2 Digitized anatomical landmarks

Thorax	
C7	Processus spinosus of the seventh cervical vertebra
T8	Processus spinosus of the eighth thoracic vertebra
IJ	Deepest point of incisura jugularis (suprasternal notch)
PX	Processus xiphoideus, most caudal point of the sternum
Clavicle	
SC	Most ventral point on the sternoclavicular joint
AC	Most dorsal point on the acromioclavicular joint
Scapula	
TS	Trigonum spinae scapulae, the midpoint of the triangular surface on the medial border of the scapula in line with the scapular spine
AI	Angulus inferior, most caudal point of the scapula
AA	Angulus acromialis, most laterodorsal point of the scapula
Humerus	
EL	Most caudal point on lateral epicondyle
EM	Most caudal point on medial epicondyle

Evaluation of Cervical and Thoracic Alignment. The cervical and thoracic alignment was measured two dimensionally. This study used coordinates provided by the digitizer to measure cervical alignment and distinguished between the alignment of the upper cervical spine (cranial angle) and the lower cervical spine (cervical angle) (Edmondston et al., 2007; Straker et al., 2009). To evaluate cranial and the cervical angles, the corner of the right eye, the tragus of the right ear, and the spinous process of the 7th cervical vertebra were digitized. The coordinates of these anatomical landmarks were used to calculate the cranial and the cervical angles illustrated in Figure 2. To measure the midthoracic curve (MTC), the digitized coordinates of the spinous processes ranging from T2 to T11 were used. A curve was drawn along the thoracic spinous processes and a straight line directly between the spinous processes T2 and T11 (Figure 3). The longest perpendicular distance (h) between the curve and the straight line was calculated using the coordinates. The MTC was calculated using the formula presented on Figure 3. The line labeled length (l) is the straight-line distance between spinous processes T2 and T11. The line labeled height (h) is perpendicular to l and intersects the curve at a digitized point of the midthoracic process that

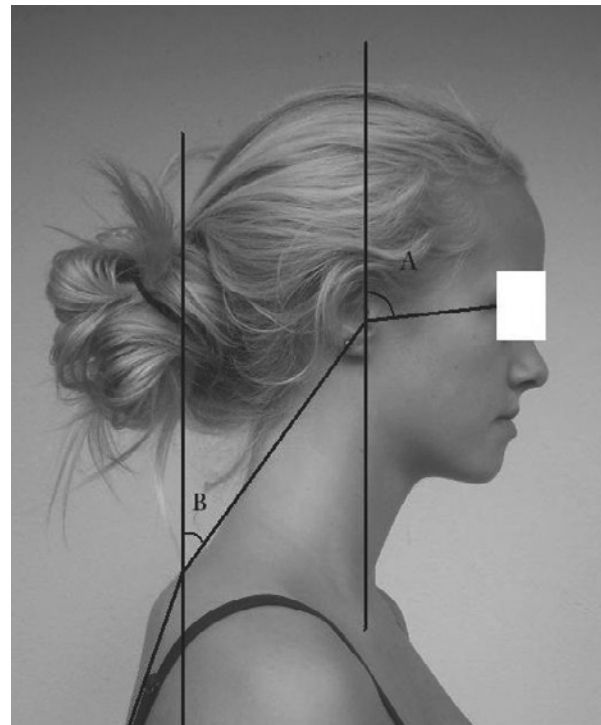


Figure 2 — Angle definitions: The corner of the right eye (canthus), the tragus of the right ear (tragus), and the spinous process of the 7th cervical vertebra (C7) were digitized. The cranial angle (A) is formed by the line of canthus to tragus with respect to vertical plane. The cervical angle (B) is formed by the line of tragus to C7 with respect to vertical plane.

Formula for the MTC.

$$mtc = 4 \times \left[\arctan \left(\frac{2 \times h}{l} \right) \right]$$

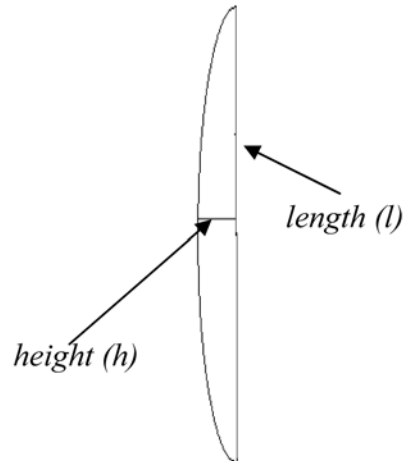


Figure 3 — Illustration and calculation measuring the midthoracic curve (MTC).

visually demonstrated the top of the curve (Bullock et al., 2005). This method in evaluating the thoracic curve has shown a good intra- and interrater reliability with a ICC level of 0,99 (Kristinsson, 2008).

Experimental Procedure. The anatomical landmarks were palpated and marked. Three Fastrak sensors were attached to each subject. Using adhesive tape, the first sensor was attached to the skin of the sternum (distal to the sternal notch) and the second sensor to the flat part of the acromion. The second sensor evaluated the clavicle and scapular rotations. The third sensor, attached to an elastic strap (Mylatex wrap, 45 cm, Chattanooga Group, USA), was placed distally on posterior aspect of humerus proximal to the epicondyles. These placements have been used previously and validated for these measurements (Karduna et al., 2001; Ludewig & Cook, 2000). The height of the chair used in the study was adjusted for each subject, and a 15 degree obliquely aligned cushion was used to facilitate neutral spinal curves.

The subject was instructed to sit in a comfortable upright position such that the sacrum was in contact with the back of the chair with the feet placed parallel on the floor (Figure 4). The following instructions were verbalized to each subject: “Visually focus on a point, directly ahead, on the chart in front of you.” “Allow your hands, shoulders, and arms to assume the position they would normally assume by the side.” The subject was instructed to maintain this position throughout the digitization and the GH estimation procedures. Following this, the raw data from the sensors were converted into anatomically defined rotations (Karduna et al., 2001). The right and left sides were assessed separately. Two measurements were conducted on each subject on both sides (the Fastrak sensors on the scapula and the arm had to be moved to the opposite side). The two measurements were averaged to get one measure for each side. The order of testing was randomized (sides and groups).

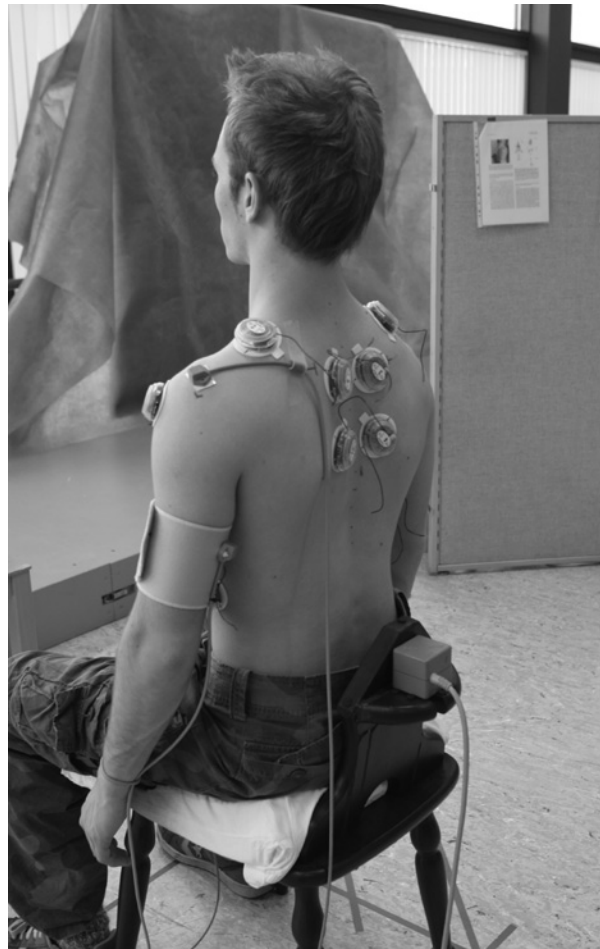

Figure 4 — Experimental setup. A sensor was attached to the skin of the sternum, to the flat part of the acromion and on the posterior aspect of the humerus. The EMG surface electrodes on the subject were not used in this study.

The subjects were not aware that the alignment of the spine and the shoulder girdle was measured. They were informed that the function of the upper body was evaluated by using surface EMG electrodes (not part of this study). The alignment measurements were conducted before the subject elevated the arm several times.

Data Analysis

The R version 2.8.0 (R Foundation for Statistical Computing) was used for statistical analysis. The age, weight, and height between the three groups were compared by ANOVA. The main parameter of interest was the alignment of the shoulder girdle and cervical and thoracic spine with the arms resting by the side. The data for the alignment of the shoulder girdle was described using two clavicle rotations—elevation/depression and retraction/protraction, and by three scapular rotations—upward/downward rotation, internal/external rotation, and anterior/posterior tilt, as dependent variables (Figure 1). A software program (KINE, Hafnarfjordur, Iceland) calculated the orientation of each clavicle and scapular rotation.

Three variables were related to the alignment of the cervical and thoracic spine: cranial angle, cervical angle, and midthoracic curve (Figure 2 and 3). The calculation for the alignment of the cervical and thoracic spine was performed automatically by the use of an Excel software program (Bullock et al., 2005).

For each group, means and standard deviations were calculated for the five dependent variables on each side demonstrating alignment of the shoulder girdle and the three dependent variables demonstrating cervical and thoracic alignment. As the Shapiro test did not reject normal distribution of the data, parametric tests were used for statistical analysis. Initial analyses were performed to test for possible group differences, in the dependent measures, by using general linear model one-way ANOVA, and the Tukey honest significant difference method was used to determine the main effects of the ANOVA. The correlation between the dependent variables and the scores on the NDI and the VAS was also assessed. The significance level for all tests was set at 0.05.

Results

There was no significant difference in age, weight, and height among the three groups or between the results of men and women within each group (Table 1). The ANOVA revealed on the right side a significant difference in clavicle retraction ($p < .03$) and on the left side a significant difference in clavicle elevation ($p = .01$), scapular tilt ($p < .01$), and scapular upward rotation ($p < .03$) among the three groups. A significant difference was also observed in the cranial angle ($p < .01$) and a tendency in the cervical angle ($p = .07$), but no difference was found in the midthoracic curve ($p = .99$) among the three groups.

The correlation between the dependent variables and the scores on the NDI and VAS was found to be weak ($r < .50$). Summary group data are demonstrated on Table 3 and Figure 5.

Post hoc comparison on the right side revealed a significantly reduced clavicle retraction in the IONP group ($p = .04$) and in the WAD group ($p < .02$) compared with the control group. On the left side, there was a significantly reduced scapular upward rotation in the WAD group ($p < .03$) and reduced clavicle elevation in the IONP group ($p = .02$) compared with the control group. A different manifestation was observed between the symptomatic groups for the left side demonstrated by a significantly increased scapular anterior tilt in the WAD group compared with the control group ($p = .01$) and the IONP group ($p < .01$).

Post hoc comparison of the cranial angle showed significantly decreased cranial angle in the IONP group ($p = .02$) and the WAD group ($p = .03$) compared with the control group.

Discussion

The results of this study support the hypothesis of altered alignment of the shoulder girdle and the cervical spine in patients with neck pain compared with asymptomatic subjects. The weak correlation between the alignment of the cervical spine and shoulder girdle and the level of pain and disability suggests that pain or impairment in the neck area may partly be associated with alignment that is probably multifactorial in its genesis.

The side-to-side differences in the asymptomatic group correspond to those of former studies, where clavicle elevation and retraction is typically reduced on the dominant side compared with the nondominant side (Sobush et al., 1996) and scapular upward rotation is increased on the nondominant side compared with the dominant side (Crosbie et al., 2008). As the majority of patients that participated in this study had bilateral symptoms in the neck area, the side-to-side differences cannot be related to increased symptoms on the left side but rather to less usage and less awareness of the nondominant arm compared with the dominant arm (Sandlund et al., 2006).

The reduced clavicle retraction and cranial angle observed in the symptomatic groups are consistent with previous reports that a forward head posture and a combination of lower cervical flexion, upper cervical extension, and reduced clavicle retraction are more common in patients with neck pain compared with asymptomatic subjects (Braun, 1991; Szeto et al., 2002; Yip et al., 2008). This may lead to increased compressive forces in the articulations of the cervical and thoracic spine, inducing tension in the muscles in the area (Harrison et al., 2004; Szeto et al., 2002; Yip et al., 2008) and affecting the muscle activity of the trapezius and the serratus anterior (Weon et al., 2010). Reduced median nerve sliding and

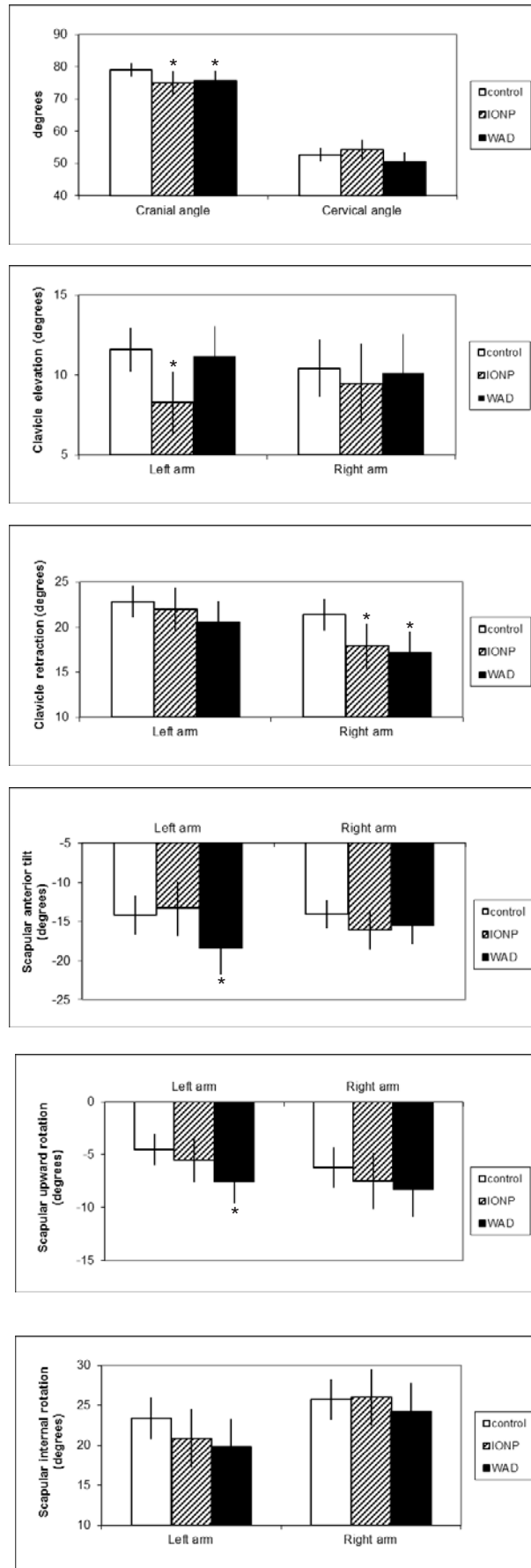


Figure 5 — Columns demonstrating the mean and the 95% confidence intervals of the cranial angle, cervical angle, clavicle elevation and retraction, and scapular anterior tilt, upward rotation and internal rotation in the three groups. * $p < 0.05$.

Table 3 Group comparison: *p* values of the clavicle elevation and retraction, and scapular tilt, upward rotation, and internal rotation

	Left Side			Right Side		
	IONP/control	WAD/control	IONP/WAD	IONP/control	WAD/control	IONP/WAD
Elevation (+)	0.02*	0.99	0.20	0.99	1.00	0.99
Retraction (+)	0.99	0.70	0.92	0.04*	0.02*	0.99
Anterior tilt (–)	0.99	0.01*	0.00*	0.74	0.81	0.99
Upward rotation (+)	0.89	0.03*	0.77	0.69	0.26	0.99
Internal rotation (+)	0.75	0.20	0.99	1.00	0.89	0.88

Note. **p* < 0.05.

paresthesias have also been associated with reduced clavicle retraction (Julius et al., 2004).

The reduced clavicle retraction may be connected to a decreased ability of trapezius to retract and maintain the normal position of the scapula. The middle trapezius functions as a scapula retractor and the transversely orientated fibers of the upper and lower trapezius assist in this action (Johnson et al., 1994). Reduced extensibility in the pectoralis minor muscle is also of interest because of its attachment to the medial border of the coracoid process on the scapula, but the pectoralis major muscle influence may not be so significant while the arms are resting by the sides (Sahrmann, 2002).

The differences in the cranial angle may be caused by an increased lordotic alignment of the atlas, which is the main lordotic segment in the cervical spine (Kristjánsson, 2004). The decreased cranial angle and differences in the cervical lordosis may reflect altered muscle activity in the deep cervical flexors observed in patients with neck pain. Interestingly, an increased activity has been observed in the sternocleidomastoid and the anterior scaleni muscles with altered motor control strategies of the deep cervical flexors (Falla et al., 2004b; Falla & Farina, 2005; Jull et al., 2004a; Jull et al., 2004b; Szeto et al., 2005a). It has been suggested that the increased cranial angle in the upper cervical spine, noted in the WAD group is a compensation strategy for the reduced weight-bearing capacity of the cervical spine after motor vehicle collisions (Kristjánsson, 2004). Altered activity in the cervical flexors in patients with WAD may develop because of pain and the aforementioned biomechanical changes (Kristjánsson, 2004).

The interesting results in this study were the increased anterior tilt and reduced upward rotation of the scapula and the reduced clavicle elevation. These findings have not been reported previously in patients with neck pain. The different manifestation that was revealed between the two symptomatic groups in clavicle elevation and scapular anterior tilt on the left side (nondominant) is an important finding suggesting that a difference may exist in impairments between these groups. A different manifestation has been reported in the alignment of the shoulder girdle between patients with shoulder

problems, wherein patients with instability demonstrated less-elevated shoulders and patients with impingement syndrome more elevated shoulders on the symptomatic side compared with the asymptomatic side (Warner et al., 1992). A difference in the activity of the upper trapezius has been reported between patients with WAD and IONP in which patients with WAD had a tendency for higher and longer muscle activation patterns in trapezius during upper-limb tasks (Nederhand et al., 2002), reduced ability to relax after tasks (Fredin et al., 1997), and demonstrated a significantly higher EMG amplitude in the muscle compared with patients with IONP (Falla et al., 2004a).

The increased anterior tilt of the scapula in the WAD group might be associated with forward head posture (Thigpen et al., 2010) and short overactive pectoralis minor muscle associated with inefficiency in the serratus anterior and lower trapezius muscles that fail to control the anterior tilt of the scapula (Borstad & Ludewig, 2005; Ludewig & Cook, 2000; Sahrmann, 2002).

The reduced clavicle elevation observed in the IONP group is consistent with previous reports in patients with tension-type headache for whom an intermediate lateral projection of an X-ray spinogram was used to determine the position of the shoulder girdle. The lower cervical and upper thoracic spine is generally obscured by the shoulder girdle. The term *low-set shoulder* was used to refer to cases where the first thoracic vertebra (mild cases) and upper third or more of the second thoracic vertebra (severe cases) were clearly visualized. In the controls (*n* = 225), a mild low-set shoulder was observed in 38% (*n* = 86) of the subjects but severe in only 3.8% (*n* = 8). In patients with tension-type headache (*n* = 372), 48% (*n* = 180) had mild low-set shoulders and 9.1% (*n* = 34) severe (Nagasawa et al., 1993). The reduced clavicle elevation may reflect inefficiency of the upper trapezius, which fails to control normal clavicle elevation against gravity (Mottram et al., 2009; Sahrmann, 2002) or an imbalance between the upper and lower trapezius muscles such that the activity of the lower trapezius may dominate the activity of the upper trapezius (Ludewig et al., 1996).

The combination of reduced clavicle elevation and reduced scapular anterior tilt demonstrated in the IONP

group on the left side supports recent suggestions that increased clavicle elevation is coupled with increased scapular anterior tilt and vice versa (Teece et al., 2008). The reduced scapular anterior tilt in the IONP group on the left side may therefore correspond to the decreased clavicle elevation. However, the reduced anterior tilt may also occur due to increased activity in the levator scapulae and the rhomboid muscles, to compensate for inefficient upper trapezius (Ludewig et al., 1996; Sahrman, 2002).

The reduced scapular upward rotation reflects either long, inefficient upper trapezius and serratus anterior muscles or short overactive levator scapulae and rhomboid muscles, which would simultaneously elevate and retract the clavicle, and downwardly rotate the scapula (Sahrman, 2002). The reduced clavicle elevation in the IONP group and the reduced scapular upward rotation in the WAD group are concurrent with Sahrman's (2002) statement that the most common alignment impairments of the shoulder girdle in patients with shoulder pain is the downwardly rotated alignment of the scapula and the depressed alignment of the clavicle. It should be noted that a reduced clavicle elevation as well as a reduced scapular upward rotation maintains a lengthen position of the upper trapezius, which induces excessive strain on the muscle as well as the levator scapula and the rhomboid muscles. This lengthen position increases tenderness in the muscles (Azevedo et al., 2008) and inflicts compressive, rotational, and shear forces on the cervical and thoracic spine, which may be an important mechanism associated with the maintenance for recurrence or exacerbation of neck pain (Behrsin & Maguire, 1986; Jull, 1997; Jull et al., 2004b, 2008; Mottram et al., 2009). This corresponds to studies demonstrating reduced neck symptoms when patients with neck pain rotate the neck when the shoulder girdle is passively elevated (Van Dillen et al., 2007).

The primary limitation of this study is that it describes only the alignment of the spine and the shoulder girdle at rest and therefore the findings cannot be generalized to alignment during functional tasks, especially when the upper limb is moving or loaded. This is also the case when activities are prolonged over time. Secondly, the fact that the measurements were done in sitting may be considered a limitation of the study, since a difference in the sitting position between the three groups may have led to differences observed. However, the sitting position was standardized by adjusting the height of the chair for each subject, by using an obliquely aligned cushion, by ensuring that the sacrum was in contact with the back of the chair, and by placing the feet parallel on the floor. Because the results demonstrate an equivalent alignment of the thoracic spine in all three groups ($p = .99$), it may be concluded that the sitting position was similar in all three groups and therefore did not affect the results of the study. Thirdly, the results present mean values for each group, but a great variability was observed within each group. Fourthly, evaluating for restriction in extensibility in the pectoralis minor muscle may have provided information

about the relationship of a restriction to altered alignment of the shoulder girdle.

Conclusions

A reduced clavicle retraction, scapular upward rotation, and cranial angle were observed in patients with neck pain compared with asymptomatic subjects. A different manifestation was observed between patients with IONP and WAD on the left side in clavicle elevation and scapular anterior tilt, suggesting that a difference may exist in impairments between these groups. The WAD group revealed increased anterior tilt of the left scapula compared with the control group and the IONP group, which revealed a reduced clavicle elevation on the left side compared with the control group.

References

- Azevedo, D.C., de Lima Pires, T., de Souza Andrade, F., & McDonnell, M.K. (2008). Influence of scapular position on the pressure pain threshold of the upper trapezius muscle region. *European Journal of Pain (London, England)*, *12*, 226–232.
- Behrsin, J., & Maguire, K. (1986). Levator scapulae action during shoulder movement: A possible mechanism for shoulder pain of cervical origin. *The Australian Journal of Physiotherapy*, *32*, 101–106.
- Biryukova, E.V., Roby-Brami, A., Frolov, A.A., & Mokhtari, M. (2000). Kinematics of human arm reconstructed from spatial tracking system recordings. *Journal of Biomechanics*, *33*, 985–995.
- Borstad, J.D., & Ludewig, P.M. (2005). The effect of long versus short pectoralis minor resting length on scapular kinematics in healthy individuals. *Journal of Orthopaedic & Sports Physical Therapy*, *35*, 227–238.
- Braun, B.L. (1991). Postural differences between asymptomatic men and women and craniofacial pain patients. *Archives of Physical Medicine and Rehabilitation*, *72*, 653–656.
- Bullock, M.P., Foster, N.E., & Wright, C.C. (2005). Shoulder impingement: The effect of sitting posture on shoulder pain and range of motion. *Manual Therapy*, *10*, 28–37.
- Crosbie, J., Kilbreath, S.L., Hollmann, L., & York, S. (2008). Scapulohumeral rhythm and associated spinal motion. *Clinical Biomechanics (Bristol, Avon)*, *23*, 184–192.
- Edmondston, S.J., Chan, H.Y., Ngai, G.C., Warren, M.L., Williams, J.M., Glennon, S., et al. (2007). Postural neck pain: An investigation of habitual sitting posture, perception of 'good' posture and cervicothoracic kinaesthesia. *Manual Therapy*, *12*, 363–371.
- Edmondston, S.J., Henne, S.E., Loh, W., & Ostvold, E. (2005). Influence of cranio-cervical posture on three-dimensional motion of the cervical spine. *Manual Therapy*, *10*, 44–51.
- Elliott, J., Sterling, M., Noteboom, J.T., Darnell, R., Galloway, G., & Jull, G. (2008). Fatty infiltrate in the cervical extensor muscles is not a feature of chronic, insidious-onset neck pain. *Clinical Radiology*, *63*, 681–687.
- Falla, D., Bilenkij, G., & Jull, G. (2004a). Patients with chronic neck pain demonstrate altered patterns of muscle activation during performance of a functional upper limb task. *Spine*, *29*, 1436–1440.

- Falla, D., & Farina, D. (2005). Muscle fiber conduction velocity of the upper trapezius muscles during dynamic contraction of the upper limb in patients with chronic neck pain. *Pain, 116*, 138–145.
- Falla, D., Farina, D., & Graven-Nielsen, T. (2007a). Experimental muscle pain results in reorganization of coordination among trapezius muscle subdivisions during repetitive shoulder flexion. *Experimental Brain Research, 178*, 385–393.
- Falla, D., Jull, G., & Hodges, P.W. (2004b). Feedforward activity of the cervical flexor muscles during voluntary arm movements is delayed in chronic neck pain. *Experimental Brain Research, 157*, 43–48.
- Falla, D., O'Leary, E.F., Fagan, A., & Jull, G. (2007b). Recruitment of the deep cervical flexor muscles during a postural-correction exercise performed in sitting. *Manual Therapy, 12*, 139–143.
- Finley, M.A., & Lee, R.Y. (2003). Effect of sitting posture on 3-dimensional scapular kinematics measured by skin-mounted electromagnetic tracking sensors. *Archives of Physical Medicine and Rehabilitation, 84*, 563–568.
- Fredin, Y., Elert, J., Britschgi, N., Nyberg, V., Vaher, A., & Gerdle, B. (1997). A decreased ability to relax between repetitive muscle contractions in patients with chronic symptoms after whiplash trauma of the neck. *Journal of Musculoskeletal Pain, 5*, 55–70.
- Harrison, D.D., Harrison, D.E., Janik, T.J., Cailliet, R., Ferantelli, J.R., Haas, J.W., et al. (2004). Modeling of the sagittal cervical spine as a method to discriminate hypolordosis: Results of elliptical and circular modeling in 72 asymptomatic subjects, 52 acute neck pain subjects, and 70 chronic neck pain subjects. *Spine, 15*, 2485–2492.
- Harryman, D.T., 2nd, Sidles, J.A., Clark, J.M., McQuade, K.J., Gibb, T.D., & Matsen, F.A., 3rd. (1990). Translation of the humeral head on the glenoid with passive glenohumeral motion. *The Journal of Bone and Joint Surgery, 72*, 1334–1343.
- Hartling, L., Brison, R.J., Ardern, C., & Pickett, W. (2001). Prognostic value of the quebec classification of whiplash-associated disorders. *Spine, 26*, 36–41.
- Janda, V. (1994). Muscles and motor control in cervicogenic disorders: Assessment and management. In: Grant, ed. *Physical therapy of the cervical and thoracic spine*. New York: Churchill Livingstone.
- Johnson, G.M., Bogduk, N., Nowitzke, A., & House, D. (1994). Anatomy and action of trapezius muscle. *Clinical Biomechanics (Bristol, Avon), 9*, 44–50.
- Julius, A., Lees, R., Dilley, A., & Lynn, B. (2004). Shoulder posture and median nerve sliding. *BMC Musculoskeletal Disorders, 5*:23. doi:10.1186/1471-2474-5-23.
- Jull, G. (1997). Management of cervical headache. *Manual Therapy, 2*, 182–190.
- Jull, G., Kristjánsson, E., & Dall'Alba, P. (2004a). Impairment in the cervical flexors: A comparison of whiplash and insidious onset neck pain patients. *Manual Therapy, 9*, 89–94.
- Jull, G., Sterling, M., Falla, D., Treleaven, J., & O'Leary, S. (2008). *Whiplash headache and neck pain: Research-based directions for physical therapies*. Edinburgh, UK: Churchill Livingstone, Elsevier.
- Jull, G.A., Falla, D., Treleaven, J., Sterling, M., & O'Leary, S. (2004b). A therapeutic exercise approach for cervical disorders. In: J. Boyling and G. Jull, ed. *Grieve's modern manual therapy: The vertebral column*. Edinburgh, UK: Churchill Livingstone, Elsevier Science (3 ed.).
- Karduna, A., McClure, P., Michener, L., & Senett, B. (2001). Dynamic measurements of three-dimensional scapular kinematics: A validation study. *Journal of Biomechanical Engineering, 123*, 184–190.
- Kebaetse, M., McClure, P., & Pratt, N.A. (1999). Thoracic position effect on shoulder range of motion, strength, and three-dimensional scapular kinematics. *Archives of Physical Medicine and Rehabilitation, 80*, 945–950.
- Kibler, W.B., & McMullen, J. (2003). Scapular dyskinesis and its relation to shoulder pain. *The Journal of the American Academy of Orthopaedic Surgeons, 11*, 142–151.
- Kristinsson, B.M. (2008). Áreyðanleiki og réttmæti mælingar brjóstbaksveigju fólks með þrívíddargreini og samamburður aðferðarinnar við Cobb hornið. *Lokaverkefni til B.S. prófs við Háskóla Íslands (BS Thesis), May*.
- Kristjánsson, E., & Jonsson, H., Jr. (2002). Is the sagittal configuration of the cervical spine changed in women with chronic whiplash syndrome? A comparative computer-assisted radiographic assessment. *Journal of Manipulative and Physiological Therapeutics, 25*, 550–555.
- Kristjánsson, E.B. (2004). *Clinical characteristics of whiplash associated disorder (WAD), grades I-II: Investigation into the stability system of the cervical spine.*, University of Iceland, Reykjavík. PhD Thesis.
- Kuhn, J.E., Plancher, K.D., & Hawkins, R.J. (1995). Scapular winging. *The Journal of the American Academy of Orthopaedic Surgeons, 3*, 319–325.
- Ludewig, P.M., & Cook, T.M. (2000). Alterations in shoulder kinematics and associated muscle activity in people with symptoms of shoulder impingement. *Physical Therapy, 80*, 276–291.
- Ludewig, P.M., Cook, T.M., & Nawoczenski, D.A. (1996). Three-dimensional scapular orientation and muscle activity at selected positions of humeral elevation. *Journal of Orthopaedic & Sports Physical Therapy, 24*, 57–65.
- Ludewig, P.M., Phadke, V., Braman, J.P., Hassett, D.R., Cieminiski, C.J., & LaPrade, R.F. (2009). Motion of the shoulder complex during multiplanar humeral elevation. *The Journal of Bone and Joint Surgery, 91*, 378–389.
- Magee, D.J. (1987). *Orthopedic physical assessment*. Philadelphia, PA: WB Saunders Company.
- Michener, L.A., McClure, P.W., & Karduna, A.R. (2003). Anatomical and biomechanical mechanisms of subacromial impingement syndrome. *Clinical Biomechanics, 18*, 369–379.
- Mottram, S.L., Woledge, R.C., & Morrissey, D. (2009). Motion analysis study of a scapular orientation exercise and subjects' ability to learn the exercise. *Manual Therapy, 14*, 13–18.
- Nagasawa, A., Sakakibara, T., & Takahashi, A. (1993). Roentgenographic findings of the cervical spine in tension-type headache. *Headache, 33*, 90–95.
- Nederhand, M.J., Hermens, H.J., Ijzerman, M.J., Turk, D.C., & Zilvold, G. (2002). Cervical muscle dysfunction in chronic whiplash-associated disorder grade 2: The relevance of the trauma. *Spine, 27*, 1056–1061.
- Sahrmann, S.A. (2002). *Diagnosis and treatment of movement impairment syndromes*. St. Louis: Mosby Inc.
- Sandlund, J., Djupsjöbacka, M., Ryhed, B., Hamberg, J., & Björklund, M. (2006). Predictive and discriminative value of shoulder proprioception tests for patients with whiplash-associated disorders. *Journal of Rehabilitation Medicine, 38*, 44–49.
- Sobush, D.C., Simoneau, G.G., Dietz, K.E., Levene, J.A., Grossman, R.E., & Smith, W.B. (1996). The Lennie test

- for measuring scapular position in healthy young adult females: A reliability and validity study. *Journal of Orthopaedic & Sports Physical Therapy*, 23, 39–50.
- Spitzer, W.O., Skovron, M.L., Salmi, L.R., Cassidy, J.D., Duranceau, J., Suissa, S., et al. (1995). Scientific monograph of the Quebec task force on whiplash-associated disorders: Redefining “whiplash” and its management. *Spine*, 15, 1S–73S.
- Sterling, M., Jull, G., & Wright, C. (2001). The effect of musculoskeletal pain on motor activity and control. *The Journal of Pain*, 2, 135–145.
- Straker, L.M., O’Sullivan, P.B., Smith, A.J., & Perry, M.C. (2009). Relationships between prolonged neck/shoulder pain and sitting spinal posture in male and female adolescents. *Manual Therapy*, 14, 321–329.
- Szeto, G.P.Y., Straker, L.M., & O’Sullivan, P.B. (2005a). A comparison of symptomatic and asymptomatic office workers performing monotonous keyboard work - 1: Neck and shoulder muscle recruitment patterns. *Manual Therapy*, 10, 270–280.
- Szeto, G.P.Y., Straker, L.M., & O’Sullivan, P.B. (2005b). A comparison of symptomatic and asymptomatic office workers performing monotonous keyboard work - 2: Neck and shoulder kinematics. *Manual Therapy*, 10, 281–291.
- Szeto, G.P.Y., Straker, L.M., & Raine, S. (2002). A field comparison of neck and shoulder postures in symptomatic and asymptomatic office workers. *Applied Ergonomics*, 33, 75–84.
- Teece, R.M., Lunden, J.B., Lloyd, A.S., Kaiser, A.P., Cieminiski, C.J., & Ludewig, P.M. (2008). Three-dimensional acromioclavicular joint motions during elevation of the arm. *The Journal of Orthopaedic and Sports Physical Therapy*, 38, 181–190.
- Thigpen, C.A., Padua, D.A., Michener, L.A., Guskiewicz, K., Giuliani, C., Keener, J.D., et al. (2010). Head and shoulder posture affect scapular mechanics and muscle activity in overhead tasks. *Journal of Electromyography and Kinesiology*, 20, 701–709.
- Van Dillen, L.R., McDonnell, M.K., Susco, T.M., & Sahrman, S.A. (2007). The immediate effect of passive scapular elevation on symptoms with active neck rotation in patients with neck pain. *The Clinical Journal of Pain*, 23, 641–647.
- Vernon, H., & Mior, S. (1991). The neck disability index: A study of reliability and validity. *Journal of Manipulative and Physiological Therapeutics*, 14, 409–415.
- Warner, J.J., Micheli, L.J., & Arslania, L.E. (1992). Scapulothoracic motion in normal shoulders and shoulders with glenohumeral instability and impingement syndrome: A study using Moire topographic analysis. *Clinical Orthopaedics and Related Research*, 285, 191–199.
- Weon, J.-H., Oh, J.-S., Cynn, H.-S., Kim, Y.-W., Kwon, O.-Y., & Yi, C.-H. (2010). Influence of forward head posture on scapular upward rotators during isometric shoulder flexion. *Journal of Bodywork and Movement Therapies*, 14, 367–374.
- Williams, P.L., & Warwick, R. (1980). *Gray’s anatomy* (36th ed.). Edinburgh: Churchill Livingstone.
- Wu, G., van der Helm, F.C.T., Veeger, H.E.J., Makhsoos, M., Van Roy, P., Anglin, C., et al. (2005). ISB recommendation on definitions of joint coordinate systems of various joints for the reporting of human joint motion - Part II: Shoulder, elbow, wrist and hand. *Journal of Biomechanics*, 38, 981–992.
- Yip, C.H.T., Chiu, T.T.W., & Poon, A.T.K. (2008). The relation between head posture and severity and disability of patients with neck pain. *Manual Therapy*, 13, 148–154.